



Clinical Features, Neuroimaging, and Levodopa-Responsiveness in Holmes' Tremor: A Video-Based Case-Series with a Review of the Literature

Anumeha Mishra, MD  and Sanjay Pandey, MD, DM* 

Abstract: **Background:** Holmes' tremor (HT) is a low-frequency tremor characterized by a combination of rest, posture, and action components. We are reporting the clinical features, neuroimaging findings, and levodopa responsiveness in 12 patients with HT.

Cases: The majority of the patients were male (11/12). Dystonia was observed in 10 patients and the remaining two patients had head tremor, a "forme-fruste" of cervical dystonia. The underlying etiologies were vascular (n = 8), head trauma (n = 2), and tumor resection (n = 2). Neuroimaging showed isolated involvement of the midbrain in four, thalamus in two, and basal ganglia and cerebellum in one patient each. A combination of the lesion (thalamus and cerebellum = 2; cerebellopontine angle = 1, and cortical/subcortical = 1) was present in four patients. Levodopa responsiveness was seen in 75% of patients including one with levodopa-induced dyskinesia.

Literature Review: Of 139 patients from 49 studies, levodopa was tried in 123 patients. Improvement with levodopa was seen in 71 patients (57.72%). No improvement with levodopa was observed in 33 patients (26.82%) and details regarding therapeutic response were unavailable in 19 patients (15.44%).

Conclusions: Dystonia is an important clinical manifestation of HT. Levodopa responsiveness seen in the majority of the patients is consistent with the hypothesis that nigrostriatal pathway damage is crucial for the pathophysiology of HT.

Although eponymous with Gordon Holmes who provided a rather detailed account of Holmes' tremor (HT) in an essay titled "On certain tremors in organic cerebral lesions" in 1904, it was Benedikt who described this entity as early as 1889.^{1,2} Holmes chronicled this tremor as a coarse irregular 3 to 4 Hz tremor, although present at rest would enhance markedly on assumption of a posture. The clinical phenomenology of HT is complex and might be accompanied by symptoms of dystonia, choreoathetoid movements, and ataxia. A question has also been raised about whether HT should be classified within the dystonic tremor syndromes.³ Considering the marked clinical heterogeneity there has been a recent attempt to subclassify HT into two distinct types, thalamic and midbrain types.⁴ However, the structural

lesions associated with HT have also been reported in the cerebellum, pons, medulla, and rarely multiple cortical sites.^{3,5,6} The pathophysiology of HT remains speculative and a parallel dysfunction of cerebellothalamic and nigrostriatal pathways has been postulated to produce this type of tremor.⁴⁻¹⁰ Furthermore, there are various accounts of HT being responsive to levodopa (L-dopa), which supports the role of striatonigral system in the causation. There are several reports of responsiveness of HT to L-dopa and to other dopaminomimetic agents; however, a systematic review of L-dopa responsiveness has not been published in the literature to the best of our knowledge. In this paper, we report a series of 12 patients with HT and discuss the clinical features, associated neurologic findings, localization of

Department of Neurology, Govind Ballabh Pant Postgraduate Institute of Medical Education and Research, New Delhi, India

***Correspondence to:** Dr Sanjay Pandey, Professor, Department of Neurology, Academic Block, Room No 501, Department of Neurology, Govind Ballabh Pant Postgraduate Institute of Medical Education and Research, New Delhi 110002, India; E-mail: sanjayspggi2002@yahoo.co.in

Keywords: tremor, dystonia, levodopa.

Relevant disclosures and conflict of interest are listed at the end of this article.

Received 1 February 2022; revised 27 May 2022; accepted 4 June 2022.

Published online 7 July 2022 in Wiley Online Library (wileyonlinelibrary.com). DOI: 10.1002/mdc3.13501

the incriminating lesion, imaging correlations, and response to L-dopa treatment.

Case Series

Methods

This is a case series of 12 patients with HT who attended our movement disorder clinic over the past 2 years and were diagnosed using the recent consensus statement from the Movement Disorders Society.¹¹ Written informed consent was obtained from all patients for the publication of their videos (see Videos 1 and 2). In addition to demographic data details regarding age at the time of the brain lesion, latency between brain lesion and tremor onset, characteristics of HT, associated neurologic symptoms, etiology and localization of the brain lesion based on neuroimaging findings, and the results of the treatments were noted. We could obtain magnetic resonance imaging (MRI) for 11 patients and computerized tomography of the head for one (MRI not possible in case 8 because of ventriculoperitoneal shunt) patient. All patients were treated with oral tablets of L-dopa + carbidopa (Table 1). At the end of 6 months of treatment L-dopa responsiveness was assessed by the patients by means of the Patient Global Impression of Change (PGIC) (range, 1–7).¹² A PubMed search was done, on March 31, 2022, using the keywords (L-dopa AND Holmes' tremor = 235, Holmes' tremor AND Dopamine = 389, and Holmes' tremor AND Nigrostriatal = 95). After removing the duplication, 257 articles were screened and 49 relevant articles were included in our review of the literature (Table S1). Additional PubMed search was also done using the keywords "Deep brain stimulation in Holmes' tremor." After removing the duplication, 191 articles were screened and 28 relevant articles were included in our review of the literature (Table S2).

Summary of Cases

Demographics

We had a total of 12 patients in our series, of which the overwhelming majority were men (11/12; 91.66%). The mean \pm (standard deviation [SD]) age of our patients was 31.08 + 14.24 (9–60) years and the mean \pm SD latency between brain lesion and tremor onset was 4.78 + 4.45 months (range, 5 days–1 year).

The Tremor

Seven of 12 (58.33%) of our patients, had tremor limited to a single upper limb, among which the left upper limb was involved in five patients (cases 1, 2, 3, 6, and 10) and the right upper limb in two patients (cases 7 and 8). Four patients (33.33%) had ipsilateral upper as well as lower limb involvement (cases 4, 5, 9, and 12). Bilateral upper limbs were involved in only one patient (8.33%) (case 11). A total of 83.33% of our patients (10/12) had a predominant distal

component, and only two (cases 3 and 12) of them (16.66%) had clear proximal predominance. Four patients (33.33%) had head tremor (cases 4, 8, 11, and 12) including one with a titubatory head tremor (case 12).

Other Neurologic Manifestations Associated with HT

Dystonia was present in 83.33% (10/12) of patients, which were more common in the upper limb (left upper limb = 4; right upper limb = 1) followed by the neck (n = 4; cases 1, 4, 6, and 11). Two patients (cases 8 and 12) who did not have dystonia had head tremor, which is considered a forme-fruste of cervical dystonia. Hemi-dystonia was present in two patients (cases 4 and 10) and 16.66% (2/12) of patients had abnormal tongue movements (one had dyskinesias and another had protrusion tremor). Other neurological manifestations associated with HT in our patients have been described in Table 2.

Etiology

Eight of our patients (8/12; 66.66%) had a stroke as the inciting factor making it the major etiology of HT in our series and among all these cases, 75% (6/8) had an ischemic etiology: two patients had a vasculitic infarct secondary to tubercular meningitis (cases 7 and 8), one alcoholic patient had hypertension and we suspected an underlying cardio-embolic basis for his chronic lacunar infarcts (case 6), one patient had a hemorrhagic infarct because of cortical venous thrombosis (CVT) (case 5), and causes of two patients could not be found (cases 2 and 3). Hemorrhagic stroke was found in two patients: one had midbrain bleed because of coagulopathy because of decompensated liver disease (case 1) and another had midbrain hemorrhage because of an arteriovenous malformation (case 4). Head trauma was causative in two patients (2/12; 16.66%) (cases 9 and 10) and in two (2/12; 16.66%) patients, HT followed resection of brain tumor (cases 9 and 11).

Neuroimaging Findings

In eight patients, the lesion was localized to the midbrain (n = 4), thalamus (n = 2), cerebellum (n = 1), and basal ganglia (n = 1) (Fig. 1A–X). In three patients, a combination of the lesion was observed (thalamus and cerebellum in cases 3 and 9; the cerebellopontine angle in case 11) and in one patient with CVT (case 5), the exact lesion localization could not be done because of extensive cortical and subcortical involvement.

Treatment Response

In our case-series, all patients were treated with L-dopa with a dose ranging from 300 to 600 mg (mean \pm SD: 358.33 \pm 103.74 mg) (Table 1). Eight of our patients (8/12; 66.66%) reported improvement after the L-dopa trial, but the spectrum of response varied with five patients (5/12; 41.66%) reporting very much improvement, three (3/12; 25%) of them



Video 1. Videos showing clinical phenomenology of patients (cases 1–6) with Holmes' tremor. Case 1: a 30-year-old male with a left upper limb tremor that has distal > proximal components, is present at rest, exacerbates in the outstretched position, and has a definite intention component with terminal exaggeration. Left upper limb dystonic posturing and cervical dystonia are also present. Case 2: a 55-year-old male with a left upper limb tremor that is distal > proximal predominant, is present at rest, in the outstretched position, and the intention component is seen as well. Left upper limb dystonic posturing is present. Case 3: a 20-year-old male with left upper limb tremor that has proximal > distal predominance, is present at rest, best appreciated when the arm is outstretched and has an intention component. Left upper limb dystonia is present. Case 4: a 26-year-old female with right upper and lower limb tremulousness that is distal and proximal is present at rest and a definite postural. She has right upper and lower limb dystonia, cervical dystonia with head tremor, and lingual dyskinesias. Case 5: a 35-year-old male with left upper limb distal > proximal predominant tremor. It can be best appreciated in a lateral wing-beating position. Left upper limb dystonic posturing is evident. Case 6: a 60-year-old male with a distal > proximal left upper limb tremor can be seen. A definite exacerbation is present when his arm is outstretched and an intention component with terminal exaggeration is evident. Left upper limb and cervical dystonia are also observed.

Video content can be viewed at <https://onlinelibrary.wiley.com/doi/10.1002/mdc3.13501>



Video 2. Videos showing clinical phenomenology of patients (cases 7–12) with Holmes' tremor. Case 7: a 21-year-old male with a right upper limb tremor that has distal > proximal components, exacerbates in wing-beating position, and has a definite intention component with terminal exaggeration. Mild dystonic posturing and tremor are present in the right upper limb, which is more evident in writing and spiral drawing. Mirror dystonia is observed while writing with the left hand. Case 8: a 21-year-old male with right upper limb tremor with distal > proximal predominance is present at rest. Increases when the case raises his arm. "No-no" type head tremulousness is seen. Case 9: a 24-year-old male with left upper limb tremor present at rest, in the outstretched position, and with an intention component that has terminal exaggeration. Left upper limb dystonia is seen. Case 10: a 30-year-old male with left upper limb tremor that is distal > proximal predominant, is present at rest, is visible in the outstretched position, and has an intention component as well. Left upper limb dystonic posturing is present. The last segment of the video shows flurid levodopa-induced dyskinesias in the left upper limb. Case 11: a 42-year-old male with bilateral upper limb tremulousness (distal > proximal), better visible in the left upper limb, can be seen at rest. His tremors increase when he lifts his arms overhead and an intention component can be seen in the left upper limb when he tries to touch his nose. Left upper limb dystonia and cervical dystonia with head tremor is also seen. Case 12: a 9-year-old boy with titubatory head tremor at rest. The right upper limb tremor that is present at rest and proximal is enhanced when the subject's arm is passively raised. Right lower limb tremor is present at rest and has postural exacerbation as well.

Video content can be viewed at <https://onlinelibrary.wiley.com/doi/10.1002/mdc3.13501>

reporting much improvement and one (1/12; 8.33%) reporting minimal improvement. Three patients (25%) did not report any improvement. Case 10 reported a good response with L-dopa, but developed L-dopa-induced dyskinesia in the left upper limb after 3 months of therapy, which got better after amantadine was started (100 mg tablets three times daily). In patients who improved with L-dopa, both rest and action tremor improved except in two patients (cases 5 and 9) where only rest tremor improved. Pramipexole or other dopamine agonists were not tried in our patients.

Literature Review

Levodopa Responsiveness

We have reviewed the data from 49 studies. Of 139 patients, L-dopa was tried in 123 patients (Table S1). The most common underlying etiology was stroke ($n = 81$), and head injury ($n = 18$). Multiple other dopaminergic (amantadine = 8, pramipexole = 6, piribedil = 2, carbergoline = 1, rotigotine = 1,

benserazide = 1, and entacopone = 1) drugs were used with or without L-dopa. The majority of the patients were also using other and non-dopaminergic drugs (anticholinergics, antipsychotics, antiepileptics, benzodiazepines, and beta-blockers) along with L-dopa. Improvement with L-dopa was seen in 71 patients (57.72%). In 111 patients, response to L-dopa was evaluated in the absence of other dopaminergic drugs and 63 patients had improvement (56.75%), which was marginally less than the global improvement of 57.72% not taking into account if L-dopa was or was not combined with other dopaminergic medications.

No improvement with L-dopa was observed in 33 patients (26.82%) and details were not available regarding therapeutic response in 19 patients (15.44%). Deep brain stimulation was performed in eight of these patients, (partial response to L-dopa [$n = 2$] or no response [$n = 6$]). Lesional surgery was done on two patients (because of arteriovenous malformation [$n = 1$] and poor response to L-dopa [$n = 1$]). Botulinum toxin was used in one patient who responded poorly to L-dopa. Only pramipexole was used in four patients and three had some improvement in tremor.

TABLE 1 Demographics and clinical details of patients with Holmes' tremor

Serial no. y/gender	Age, y	Latency	Limb tremor	Pre-dominance	Head tremors	Immediate etiology	Antecedent/contributory factors	Neuro-imaging	Frequency of the tremor*	Levodopa + carbidopa (100 + 25) doses	Treatment response to levodopa	Details of improvement
Case 1	30/M	11 months	Left upper limb	D > P	-	Stroke	Decompensated hepatitis B infection—chronic liver disease with coagulopathy	Right midbrain hemorrhage	3 Hz	Three tablets daily	Very much improved	Rest, action
Case 2	55/M	6 months	Left upper limb	D > P	-	Stroke	Not known	Right sided infarct in thalamus and occipital region	3 Hz	Three tablets daily	Very much improved	Rest, action
Case 3	20/M	7 days	Left upper limb	P > D	-	Stroke	Not known	Bilateral thalamic and cerebellar acute infarcts	3–4 Hz	Three tablets daily	Very much improved	Rest, action
Case 4	26/F	5 months	Right upper and lower limb	D = P	Head tremor	Stroke	Left midbrain arteriovenous malformation	Left midbrain hemorrhage	3 Hz	Three tablets daily for 2 months and then escalated to five tablets	No improvement	-
Case 5	35/M	2 months	Left upper and lower limbs	D > P	-	Stroke	Cortical venous thrombosis	Bilateral cortical/subcortical hemorrhagic infarct	4 Hz	Three tablets daily	Much improved	Rest
Case 6	60/M	1 year	Left upper limb	D > P	-	Stroke	Hypertension, ² cardio-embolic	Chronic bilateral midbrain lacunar infarcts	3 Hz	Three tablets daily	Much improved	Rest, action
Case 7	21/M	1 month	Right upper limb	D > P	-	Stroke	Tubercular meningitis with vasculitic infarct	Left thalamic infarct and temporal lobe encephalomalacia with gliosis	4 Hz	Three tablets daily	Much improved	Rest, action
Case 8	21/M	1 month	Right upper limb, head	D > P	No-no type of head tremor	Stroke	Tubercular meningitis with hydrocephalus with vasculitic infarct	Left basal ganglia infarct	4 Hz	Three tablets daily for 1 month then six tablets daily	No improvement	-
Case 9	24/M	1 year	Left upper and lower limb	D > P	-	Post-traumatic	Fell down into a dry tube well from a tree	Multiple hemorrhagic foci and gliosis in the right thalamus and left cerebellar region	3 Hz	Three tablets daily for 1 month then five tablets daily	Minimally improved	Rest
Case 10	30/M	6 months	Left upper limb	D > P	-	Post-traumatic	Road-traffic accident	Right midbrain hemorrhage	4 Hz	Three tablets daily for 3 months then stopped because of LID	Very much improved, LID	Rest, action
Case 11	42/M	1 month	Bilateral upper limbs (L > R), head	D > P	Head tremor	Post-operative	Operated for left cerebellopontine angle schwannoma	Left cerebellopontine schwannoma	3.5 Hz	Three tablets daily	Very much improved	Rest, action
Case 12	9/M	7 days	Right upper and lower limb, head	P > D	Tinabatory head tremor	Post-operative	Operated for medulloblastoma	Medulloblastoma in the cerebellum	3.5 Hz	½ tablet three times daily for 1 month then one tablet three times daily	No improvement	-

*As measured by surface electromyography at rest. Abbreviations: M, male; F, female; P, proximal; D, distal; UMN, upper motor neuron; LID, levodopa-induced dyskinesia.

TABLE 2 Details of other neurological manifestations in patients with Holmes' tremor

Case no.	Hemiparesis	Quadruparesis	Ataxia	Hemianesthesia	Rigidity/ bradykinesia	Dystonia	Vertical gaze restriction	Hemianopia	Any cranial nerve involvement	Tongue	Dysarthria	Seizures	Cognition
1	+			+		Left upper limb and cervical	+						
2	+					Left upper limb		+					Topographic memory loss
3	+		Gait			Left upper limb			Facial UMN palsy				
4	+		Ipsilateral hemiataxia			Right hemi- dystonia and cervical			Right prosis	Dyskinesia			
5	+		Ipsilateral hemiataxia			Left upper limb				Protrusion tremor	+	+	
6			Ipsilateral hemiataxia			Left upper limb and cervical							
7	+			+		Mild in right upper limb							
8		+											
9			Gait and appendicular			Left upper limb					+		Decreased concentration
10	+		Ipsilateral hemiataxia			Left hemi- dystonia							
11			Gait			Left upper limb and cervical							
12		+											

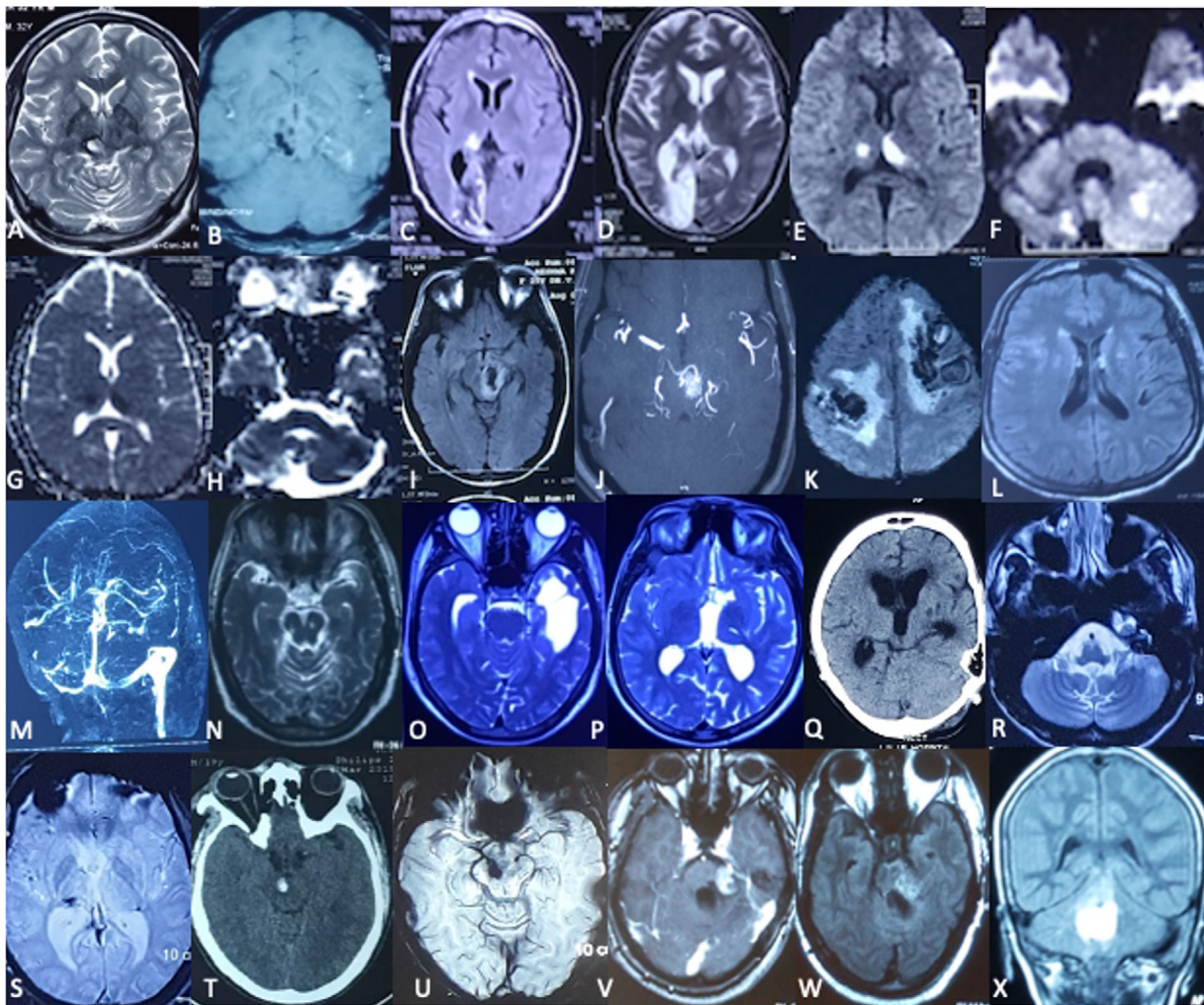


FIG. 1. Case 1: axial sections of T2-weighted (A) and gradient-recall echo (GRE) images (B) of magnetic resonance imaging (MRI) brain show right midbrain hemorrhage. Case 2: axial fluid-attenuated inversion recovery (FLAIR) (C) and T2-weighted sections (D) of MRI brain showed ischemic infarct in the right thalamus and occipital region. Case 3: axial diffusion-weighted (DWI) (E,F) and apparent diffusion coefficient (ADC) sequences (G,H) of MRI brain show bilateral acute thalamic and cerebellar infarcts. Case 4: axial FLAIR MRI brain (I) shows left mesencephalic hemorrhage. MR angiography (J) shows the causative left midbrain arteriovenous malformation. Case 5: axial GRE MRI brain (K) shows multiple bilateral cortical hemorrhagic areas admixed with infarctions because of cortical venous thrombosis. FLAIR MRI (L) is showing bilateral subcortical and periventricular white-matter changes. MR venography (M) shows attenuated right transverse and superior sagittal sinuses. Case 6: axial T2-weighted axial MRI brain (N) shows multiple chronic lacunar infarcts in the bilateral midbrain. Case 7: axial T2-weighted MRI brain images show left temporal lobe encephalomalacia with gliosis (O) and left thalamic infarct (P). Case 8: axial sections of non-contrast computerized tomography (NCCT) of the head (Q) shows multiple areas of hypodensity in the left basal ganglia region suggestive of a chronic infarct. Case 9: axial FLAIR MRI shows hyperintensities in the left cerebellar region suggestive of gliosis (R) and GRE MRI shows microbleeds in the right thalamus (S). Case 10: axial sections of NCCT head (T) and T2-GRE MRI brain show right mesencephalic hemorrhage (U). Case 11: pre-operative (V) and post-operative (W) axial FLAIR MRI brain images show left cerebellopontine angle schwannoma. Case 12: coronal pre-operative FLAIR MRI (X) shows medulloblastoma.

Deep Brain Stimulation in Holmes' Tremor

We have reviewed the data from 28 articles (Table S2). Deep brain stimulation (DBS) surgery was done in 52 patients with HT. Thirty-two patients were male and eighteen were females (data regarding two patients were not available). The most common underlying etiologies of HT were stroke (hemorrhagic: 18;

ischemic = 9), and head injury (n = 5). In hemorrhagic stroke, cavernoma (n = 7) was the most likely cause. The sites for DBS were the thalamus (isolated in 23, and combined with subthalamic nucleus [STN] in six, globus pallidus interna [GPi] in five, and caudal zona incerta [cZI] in two patients), GPi (n = 10), posterior-subthalamic-area (PSA) (n = 3), dentato-rubrothalamic tract (DRTT) (n = 2) and the prelemniscal radiations (n = 10). In the thalamus, unilateral ventral intermediate

TABLE 3 Comparison of demographic and clinical features published in large case-series (≥ 10 cases) of Holmes' tremor

	Gajos et al ⁶	Raina et al ⁵	Liu et al ¹¹	Nsengiyumva et al ⁴	This case series
Year of publication	2010	2016	2019	2020	2022
No. of patients	n = 10	n = 29	n = 23	n = 17	n = 12
Gender distribution	Five males (50%) Five females (50%)	13 males (44.82%) 16 females (55.17%)	NA	Nine males (52.94%) Eight females (47.05%)	11 males (91.66%) One female (8.33%)
Age, y	Mean age: 44.8 ± 20.2 (range, 24–84)	Mean age: 33.9 ± 20.1 (range, 8–76)	NA	Mean age: 45 ± 18.39 (range, 17–77)	Mean age: 31.08 ± 20.1 (range, 9–60)
Latency between brain lesion and tremor onset	Mean ± SD: 6.3 ± 6.9 mo (range, 1 mo–2 y)	Median = 2 mo (range, 7 d–228 mo) (data based on 25 patients only, in four patients data were not available)	Median: 29 d (range, 2 d to 20 mo)	Range: 8 wk to 14 y	Mean: 4.78 ± 4.45 mo; range (7 d–1 y)
Dystonia	Not reported	7/29 (24.13%) including three with dystonic jerks	NA	2/17 (11.76%) including one with dystonic jerk	10/12 (83.33%) (left upper limb = 4; right upper limb = 1; hemi-dystonia = 2; neck = 4 including one with jerky head tremor), 2/12 (16.67%) had head tremor
Etiology	A. Vascular: 8/10 (80%) B. Head trauma: 2/10 (20%)	A. Vascular: 14/29 (48.3%) B. Head trauma: 5/29 (17.24%) C. Miscellaneous: 10/29 (34.5%)	Most common cause: cerebrovascular disease (78.3%)	A. Vascular: 11/17 (64.70%) B. Head trauma: 2/17 (11.76%) C. Miscellaneous: 3/17 (17.64%) D. Normal MRI: 1/17 (5.88%)	A. Vascular: 8/12 (66.66%) B. Head trauma: 2/12 (28.57%) C. Post-procedure: post-tumoral resection surgery: 2/12 (16.66%)
Neuroimaging	MRI in nine cases and CT in one case showed significant involvement of thalamus (n = 5), midbrain (n = 3), pons (n = 1), and normal finding in one; SPECT in six cases did not show any major asymmetry	Imaging was abnormal in 28/29 patients (96.5%). Majority of the patients had lesions involving more than one region: the most common sites affected were midbrain in 17 (58.6%), thalamus in 16 (55.17%), and the cerebellum in 8 (27.58%). The pons was affected in 6 (20.68%) and the medulla in 1 (3.4%). Non-thalamic supratentorial lesions: 14 cases (48.27%)	The most common involved locations were midbrain (65.2%), thalamus (47.8%) and cerebellum (30.4%). Isolated lesions in 12 and multiple lesions were found in 11 cases	Imaging abnormal in all but one: 1/17 (5.88%) The most common isolated locations were midbrain (5/17 [29.41%]), thalamus (5/17 [29.41%]), and cerebellum or/and its peduncles (2/17 [11.76%])	Imaging (MRI = 9, CT = 1) was abnormal in all patients. Isolated lesions were seen in Midbrain (n = 4), Thalamus (n = 2), cerebellum (n = 1) and basal ganglia (n = 1). Combined lesions were seen in thalamus and cerebellum (n = 2), cerebellopontine angle (n = 1) and cortical/subcortical (n = 1)

(Continues)

TABLE 3 *Continued*

	Gajos et al ⁶	Raina et al ⁵	Liu et al ¹¹	Nsengiyumva et al ⁴	This case series
Dopaminergic treatment	Levodopa (n = 6); Piribedil (n = 1) with levodopa, Amantadine (n = 4) with levodopa in two patients	Levodopa therapy was tried in 24/29 patients (82.8%) (in 16 cases, the average dose was 697.65 mg ± 215 mg/day [range, 300–1000 mg/day], for eight patients, the dose could not be determined), pramipexole (n = 1)	Levodopa with clonazepam (n = 12), Levodopa alone (n = 10) (levodopa doses not available)	Levodopa (n = 16) (levodopa doses not available)	Levodopa (n = 12) Maximum doses of levodopa: (mean ± SD: 358.33 ± 103.74)
Levodopa responsiveness	Not defined Mild improvement in only two cases with levodopa therapy (150 and 400 mg), no effect with amantadine	Not defined Substantial improvement was reported in 13 (54.16%) patients whereas the remaining 11 (45.84%) had no benefit	Not defined Levodopa combined with clonazepam (7/12) and single levodopa (9/10) were partially effective	Not defined Good response in 5 (5/17 [29.41%]), no response in 10 (10/17 [58.82%]), the effect remained unknown in another (1/17 [5.88%])	PGIC scale by patient Nine patients (9/12; 75%) reported benefit with levodopa trial, which was rated as very much improvement in 5 (41.66%), much improvement in 3 (25%) and minimal improvement in one (8.33%) patient

Abbreviations: SD, standard deviation; HT, Holmes' tremor; MRI, magnetic resonance imaging; CT, computed tomography; SPECT, single photon emission computed tomography; DaTSCAN, dopamine transporter scan; AVM, arteriovenous malformation; DBS, deep brain stimulation; ICH, intracerebral hemorrhage; NA, data not available; PGIC, patient global impression of change.

nucleus (VIM) was the most common site for the stimulation. All patients had improvement in symptoms following DBS, however in the majority of the studies the improvement was not measured by specific tremor scales and the improvement in HT had a variable range.

Discussion

The overwhelming majority of our patients happen to be males. Our findings differ from the other large case series because they have reported HT in an almost equal number of males and females (Table 3).⁴⁻⁶ The latency between brain lesion and tremor onset in our patients (mean \pm SD: 4.79 \pm 4.44 months) remains coherent with the literature. However, two of our patients had acute onset of symptoms (latency = 7 days) following ischemic stroke (case 3) and post-surgical procedure (case 12). The vascular disorders remain the leading cause in our series as well with either ischemic or hemorrhagic causes being the most frequent (~66.66%), which was similar to the other large case series.^{4-6,13} Two of our patients developed symptoms of HT following resection of brain tumor and this type of presentation has been rarely reported.^{5,14}

Our case-series highlights the fact that the phenomenology spectrum of HT is quite intriguing. Tremor sometimes may change axis (eg, lateral hand tremor), depending on hand/arm position (case 10). Rest tremor can be pronation supination and then flexion and extension with arms outstretched, which sometimes may affect two or three fingers predominantly. These nuances may be overlooked if not looked at carefully.

Dystonia was present in 10 (83.33%) patients and the remaining two patients had head tremor, which is considered to be a presenting feature of cervical dystonia.¹⁵ Our findings are significant considering that the previous case series had reported dystonia in a small number of patients only.⁴⁻⁶ It may be possible that dystonia was not looked at specifically in these patients. Thalamic lesions have been reported in the majority of HT patients with dystonia.⁵ These findings are consistent with other reports suggesting that tremor resulting from thalamic lesions do not occur in isolation and are frequently associated with dystonia.¹⁶ In our patients, the thalamic lesion was present in four patients only and dystonia was also present when the lesion was localized elsewhere (midbrain, basal ganglia, and cerebellum). One of the patients had a titubatory head tremor following the surgical resection of medulloblastoma in the cerebellar region, which is similar to another case we had reported earlier.¹⁷ Our findings support the hypothesis that dystonia is a network disorder where the cerebellum plays a significant role in the pathogenesis.¹⁸

Another important observation in our study is L-dopa-responsiveness, which was seen in 75% of our patients. One of our patients developed L-dopa-induced dyskinesia after 3-month of treatment and responded to oral amantadine. This type of presentation has not been reported in the literature to the best of our knowledge. In our patients, improvement in L-dopa was

seen in both rest and action tremor except in two cases (5 and 9), where only rest tremor improved. Our findings are consistent with other case series reporting L-dopa responsiveness in all components of tremor.⁴⁻⁶

L-dopa responsiveness aligns with other data suggesting that nigrostriatal tract involvement is important for the development of HT. In 1992, Krack et al¹⁹ described two patients who displayed both cerebellar and parkinsonian signs, and based on that observation, a suggestion was made that HT develops following a combined lesion of the nigrostriatal as well cerebellothalamic projections. Later, a study using fluorodopa (F-dopa) positron emission tomography (PET) also showed that reduced putaminal L-dopa labelling was appreciated in the HT patients further revealing the role of disruption of the nigrostriatal system in the pathogenesis of HT.⁷

Deuschl et al²⁰ described a patient who, after undergoing a right hemi-cerebellectomy, presented with a parkinsonian resting tremor on the left side of his body and HT in the right upper limb. This finding further supports that a lesion involving both the nigrostriatal pathway and the cerebellar projections is required for the occurrence of resting, posture, and action tremor.²⁰ To bolster the case, several studies based on animal models have suggested that a solitary lesion in the cerebellar structures or the basal ganglia is not sufficient to induce a combined form of resting, postural, and action tremor in monkeys and that a lesion involving both structures is required in the causation of HT.^{21,22} Ohye et al²³ reported a study where animal models of HT caused by stereotactic lesions located in the midbrain ventromedial tegmental area produced a 4 to 8 Hz rest and postural tremor. Pathological examination of these lesions demonstrated damage to the substantia nigra pars compacta, nigrostriatal fibers, magnocellular and parvocellular portion of the red nucleus, and superior cerebellar outflow tract. Interestingly, in these animal models, the tremor was often expressed in the elbow-flexed posture, similar to what is seen in HT patients. Rare cases of HT with perirolandic lesions with secondary Wallerian midbrain degeneration have been reported, suggesting that the cortical node of the cerebellar-BG-thalamic-cortical loop may cause HT in some rare instances.²⁴ However, that needs replication by others.

There are several reports of the responsiveness of HT to other dopaminergic agents.²⁵⁻²⁷ Usage of dopamine agonist pramipexole led to a dramatic reduction of the resting component and gradual improvement of the kinetic component of HT in a patient reported by Strecker et al.²⁵ Similarly, in another report, treatment with pramipexole led to stark improvement of resting component of the tremor, whereas the intensity of the postural tremor remained unchanged and after an additional dose of 200 mg L-dopa/day ameliorated the postural tremor as well.²⁶ This patient also had dopaminergic denervation in the striatum ipsilateral to the lesion on β -CIT SPECT. Molecular studies have also shown that serotonergic terminals serve as a major site of the conversion of exogenous L-dopa to dopamine in the dopamine denervated striatum, which might explain this curious case.²⁸ Dopamine, by its action on direct as well as indirect

pathways of the striatal circuit, stimulates D1, D2, and D3 receptors, whereas dopamine agonist such as pramipexole has limited efficacy because their agonist activity is limited to D2 and D3 receptors and it can, therefore, only function via the indirect pathway.²⁶ In a recent study, Shi et al²⁷ published a case series of three patients with HT, who were evaluated using multimodal 3D medical imaging and treated with pramipexole. The authors speculated that the pathogenesis of tremor in one patient with a good response to pramipexole was different from the other two patients with no or poor response.

In our review of literature, improvement with L-dopa was observed in 57.72% (71/123) of patients with HT (Table S1). In other words, additional brain networks are likely to be involved, which may also explain some patients with HT having normal dopamine neuroimaging.^{6,29,30} In a recent study, Joutsa et al¹⁰ identified 36 lesions causing HT, which were scattered across multiple different brain regions. The most relevant point found by the authors was including the delineation of a brain circuit composed of the red nucleus, GPi, ventral oralis posterior (VOP) and pulvinar nuclei, pontomedullary junction, and three regions in the cerebellum (cerebellar cortex and vermis in lobule VI, and cerebellar cortex in lobule X). In addition, contrary to previous assumptions, connectivity to VIM nuclei was not found to be correlated with HT, suggesting that VOP nuclei may be a better target for DBS in HT.

HT is, by definition, a combined tremor syndrome; this is because of the co-existence of ataxia, pyramidal signs, and dystonia in the majority of patients. With this in mind, the therapeutic response to L-dopa may alleviate some aspects of the tremor, meaning amplitude, rest versus postural versus kinetic or dystonic components. This is mainly unexplored and an area of future research. In addition to the L-dopa trial for HT patients, it is important that the primary cause of brain lesion (eg, infectious, demyelinating) should be treated first. HT patients may have a strong proximal component with posture. There are some studies showing that patients with proximal tremor or “wing-beating tremor” can benefit from botulinum toxin injections in the teres major, teres minor, and supraspinatus muscles.³¹ This should be suggested for patients not responding to L-dopa.

Certain limitations should be kept in mind before interpreting the results of our study. First, our patients did not follow a standard protocol-based treatment, which may have affected the clinical outcome. Second, L-dopa responsiveness of tremor was not objectively evaluated by a neurologist, but only subjectively by the patients by means of the PGIC scale. Third, we have not done any neuroimaging to support the dopaminergic deficiency. Fourth, a detailed neurophysiological evaluation of tremor has not been done. Finally, there were some limitations in the review of literature also that was markedly affected by the incomplete data provided in various studies. We were not able to figure out the clinical and treatment details of a large number of cases. Despite all these limitations, our case series has provided a detailed phenotypic spectrum and L-dopa responsiveness in patients with HT.

We also speculate that dystonia and tremor in HT may be because of the involvement of the dopaminergic system and

could be validated in future studies. Disruption of dopaminergic pathways in the pathogenesis of dystonia has been consistently reported.^{32–34} One classic example is the dopa-responsive dystonia syndromes secondary to mutations in genes (*GCH1*, *TH*, and *SPR*) encoding enzymes involved in dopamine synthesis.^{34,35} Dopamine receptor blockers frequently cause dystonia, further supporting the role of this network in the pathophysiology of dystonia.³⁶ Neuroimaging studies have also provided evidence for reduced availability of D₂ receptors in the striatum of gene-associated dystonia (*TOR1* and *THAP*) and other types of focal dystonia such as writer's cramp.³⁷

Conclusion and Future Perspectives

In this case series, we have highlighted that dystonia of variable severity may be present in a majority of patients with HT. L-dopa responsiveness seen in 75% of our patients is consistent with the hypothesis that nigrostriatal pathway damage is crucial for the phenomenology of HT. Because dystonia is speculated to be secondary to nigrostriatal pathway involvement, future studies assessing L-dopa responsiveness may explore the differences in HT with and without dystonia. Future areas of research on HT should also include deep phenotyping of HT through detailed clinical and functional/structural imaging studies. Furthermore, it would be worthwhile to explore if L-dopa responsive HT patients would have a better response to STN DBS than to VIM DBS.

Author Roles

(1) Research project: A. Conception, B. Organization, C. Execution; (2) Statistical Analysis: A. Design, B. Execution, C. Review, and Critique; (3) Manuscript Preparation: A. Writing of the First Draft, B. Review, and Critique.

A.M.: 1A, 1B, 1C, 2A, 2B, 2C, 3A, 3B, 3C

S.P.: 1A, 1B, 1C, 2A, 2B, 2C, 3A, 3B, 3C

Disclosures

Ethical Compliance Statement: The authors confirm that the approval of an institutional review board was not required for this work. We also confirm that the patients have given written informed consent for the publication of their videos. The authors confirm that the approval of an institutional review board was not required for this work.

Funding Sources and Conflicts of Interest: No specific funding was received for this work and the authors declare that there are no conflicts of interest relevant to this work.

Financial Disclosures for the Previous 12 Months: The authors declare that there are no additional disclosures to report. ■

References

- Holmes G. On certain tremors in organic cerebral lesions. *Brain* 1904; 27(3):327–375.
- Benedikt M. Tremblement avec paralysie croisée du moteur oculaire commun. *Bull Med Paris* 1889;3:547–548.
- Deuschl G, Bain P, Brin M. Consensus statement of the Movement Disorder Society on tremor. Ad Hoc Scientific Committee. *Mov Disord* 1998;13(Suppl 3):2–23. <https://doi.org/10.1002/mds.870131303>.
- Nsengiyumva N, Barakat A, Macerollo A, et al. Thalamic versus mid-brain tremor; two distinct types of Holmes' tremor: a review of 17 cases. *J Neurol* 2021;268(11):4152–4162. <https://doi.org/10.1007/s00415-021-10491-z> Epub 2021 May 11.
- Raina GB, Cersosimo MG, Folgar SS, et al. Holmes tremor: clinical description, lesion localization, and treatment in a series of 29 cases. *Neurology* 2016;86(10):931–938.
- Gajos A, Bogucki A, Schinwelski M, et al. The clinical and neuroimaging studies in Holmes tremor. *Acta Neurol Scand* 2010;122(5):360–366.
- Remy P, De Recondo A, Defer G, et al. Peduncular/rubral tremor and dopaminergic denervation: a PET study. *Neurology* 1995;45(3):472–477.
- Raina GB, Velez M, Fernandez Pardal M, Micheli F. Holmes tremor secondary to brainstem hemorrhage responsive to levodopa: report of two cases. *Clin Neuro Pharmacol* 2007;30:95–100.
- Madelein van der Stouwe AM, Nieuwhof F, Helmich RC. Tremor pathophysiology: lessons from neuroimaging. *Curr Opin Neurol* 2020; 33(4):474–481. <https://doi.org/10.1097/WCO.0000000000000829>.
- Joutsa J, Shih LC, Fox MD. Mapping Holmes tremor circuit using the human brain connectome. *Ann Neurol* 2019;86:812–820.
- Bhatia KP, Bain P, Bajaj N, et al. Tremor task force of the International Parkinson and Movement Disorder Society. Consensus statement on the classification of tremors. From the task force on tremor of the International Parkinson and Movement Disorder Society. *Mov Disord* 2018; 33(1):75–87.
- Scott W, McCracken LM. Patients' impression of change following treatment for chronic pain: global, specific, a single dimension, or many? *J Pain* 2015;16(6):518–526. <https://doi.org/10.1016/j.jpain.2015.02.007> Epub 2015 Mar 4.
- Liu ZQ, Wan ZR, Jia XT, Yang XZ, Fang XX, Zhang ZY. Clinical features and short-term prognosis of Holmes' tremor. *Zhonghua Yi Xue Za Zhi* 2019;99(11):801–805 (Chinese). <https://doi.org/10.3760/cma.j.issn.0376-2491.2019.11.001>.
- Pandey S. Holmes' tremor secondary to cerebellopontine angle epidermoid cyst. *Neurologist* 2017;22(4):141–143. <https://doi.org/10.1097/NRL.0000000000000131>.
- Albanese A, Sorbo FD. Dystonia and tremor: the clinical syndromes with isolated tremor. *Tremor Other Hyperkinet Mov (N Y)* 2016;5(6):319. <https://doi.org/10.7916/D8X34XB>.
- Gupta N, Pandey S. Post-thalamic stroke movement disorders: a systematic review. *Eur Neurol* 2018;79(5–6):303–314. <https://doi.org/10.1159/000490070> Epub 2018 Jun 5.
- Pandey S, Jain S. Secondary cervical dystonia and titubatory head tremor. *Mov Disord Clin Pract* 2018;6(2):179–180. <https://doi.org/10.1002/mdc3.12709>.
- Kaji R, Bhatia K, Graybiel AM. Pathogenesis of dystonia: is it of cerebellar or basal ganglia origin? *J Neurol Neurosurg Psychiatry* 2018;89(5):488–492. <https://doi.org/10.1136/jnnp-2017-316250> Epub 2017 Oct 31.
- Krack P, Deuschl G, Kaps M, Warnke P, Schneider S, Traupe H. Delayed onset of "rubral tremor" 23 years after brainstem trauma. *Mov Disord* 1994;9:240–242.
- Deuschl G, Wilms H, Krack P, Würker M, Heiss WD. Function of the cerebellum in parkinsonian rest tremor and Holmes' tremor. *Ann Neurol* 1999;46:126–128.
- Brooks DJ, Playford ED, Ibanez V, Sawle GV, Thompson PD, Findley LJ, Marsden CD. Isolated tremor and disruption of the nigrostriatal dopaminergic system: an 18F-dopa PET study. *Neurology* 1992;42:1554–1560.
- Vélez M, Cosentino C, Torres L. Levodopa-responsive rubral (Holmes') tremor. *Mov Disord* 2002;17(4):741–742.
- Ohye C, Shibasaki T, Hirai T, Wada H, Kawashima Y, Hirato M, Matsumura M. A special role of the parvocellular red nucleus in lesion-induced spontaneous tremor in monkeys. *Behav Brain Res* 1988;28(1–2): 241–243. [https://doi.org/10.1016/0166-4328\(88\)90102-7](https://doi.org/10.1016/0166-4328(88)90102-7).
- Budhram A, Simpson HD, Bower JH, Hassan A, Conway BL, Flanagan EP. Holmes tremor with periorlandic demyelinating lesions: a distinct clinicoradiographic syndrome. *Neurology* 2021;96(5):231–232. <https://doi.org/10.1212/WNL.0000000000011235> Epub 2020 Nov 20.
- Strecker K, Schneider JP, Sabri O, Wegner F, Schwarz J, Hesse S. Responsiveness to a dopamine agent in Holmes tremor—case report. *Eur J Neurol* 2007;14(4):e9–e10.
- Seidel S, Kasprian G, Leutmezer F, Prayer D, Auff E. Disruption of nigrostriatal and cerebellothalamic pathways in dopamine responsive Holmes' tremor. *J Neurol Neurosurg Psychiatry* 2009;80(8):921–923.
- Shi M, Wang A, Fang Y, Guo J, Li Z, Jin S, Zhao H. Study on the pathogenesis of Holmes tremor by multimodal 3D medical imaging: case reports of three patients. *BMC Neurol* 2021;21:473. <https://doi.org/10.1186/s12883-021-02503-2>.
- Lopez A, Munoz A, Guerra MJ, Labandeira-Garcia JL. Mechanisms of the effects of exogenous levodopa on the dopamine-denervated striatum. *Neuroscience* 2001;103(3):639–651.
- Gajos A, Budrewicz S, Koszewicz M, et al. Is nigrostriatal dopaminergic deficit necessary for Holmes tremor to develop? The DaTSCAN and IBZM SPECT study. *J Neural Transm (Vienna)* 2017;124(11):1389–1393. <https://doi.org/10.1007/s00702-017-1780-1> Epub 2017 Aug 23.
- Hertel F, Züchner M, Decker C, Erken E, Libri S, Schmitt M, Bettag M. Unilateral Holmes tremor, clearly responsive to cerebrospinal fluid release, in a patient with an ischemic midbrain lesion and associated chronic hydrocephalic ventricle enlargement. Case report. *J Neurosurg* 2006;104(3):448–451. <https://doi.org/10.3171/jns.2006.104.3.448>.
- Kim SD, Yiannikas C, Mahant N, Vucic S, Fung VS. Treatment of proximal upper limb tremor with botulinum toxin therapy. *Mov Disord* 2014;29(6):835–838. <https://doi.org/10.1002/mds.25739> Epub 2013 Nov 20.
- Ribot B, Aupy J, Vidailhet M, et al. Dystonia and dopamine: from phenomenology to pathophysiology. *Prog Neurobiol* 2019;182:101678. <https://doi.org/10.1016/j.pneurobio.2019.101678> Epub 2019 Aug 9. Erratum in: *Prog Neurobiol*. 2020 Jan 9:101745.
- Ikezawa J, Yokochi F, Okiyama R, et al. Is generalized and segmental dystonia accompanied by impairments in the dopaminergic system? *Front Neurol* 2021;18(12):751434. <https://doi.org/10.3389/fneur.2021.751434>.
- Balint B, Mencacci NE, Valente EM, et al. Dystonia. *Nat Rev Dis Primers* 2018;4(1):25. <https://doi.org/10.1038/s41572-018-0023-6> Erratum in: *Nat Rev Dis Primers*. 2018 Oct 19;4(1):37.
- Ichinose H, Inagaki H, Suzuki T, Ohye T, Nagatsu T. Molecular mechanisms of hereditary progressive dystonia with marked diurnal fluctuation, Segawa's disease. *Brain Dev* 2000;22(Suppl 1):S107–S110. [https://doi.org/10.1016/s0387-7604\(00\)00136-4](https://doi.org/10.1016/s0387-7604(00)00136-4).
- Teo JT, Edwards MJ, Bhatia K. Tardive dyskinesia is caused by maladaptive synaptic plasticity: a hypothesis. *Mov Disord* 2012;27(10):1205–1215. <https://doi.org/10.1002/mds.25107> Epub 2012 Aug 1.
- Black KJ, Snyder AZ, Mink JW, Tolia VN, Revilla FJ, Moerlein SM, Perlmuter JS. Spatial reorganization of putaminal dopamine D2-like receptors in cranial and hand dystonia. *PLoS One* 2014;9(2):e88121. <https://doi.org/10.1371/journal.pone.0088121>.

Supporting Information

Supporting information may be found in the online version of this article.

Table S1. Studies reporting levodopa responsiveness in patients with Holmes' tremor.

Table S2. Studies reporting deep brain stimulation in patients with Holmes' tremor.